

## Is it Worthy Doing Primary Repair of Unilateral Cleft Lip Nasal Deformity Simultaneously with Lip Repair

ASHRAF MOHAMED ENAB, M.D.\*; AHMED B. GENIDEY, M.Sc.\*; DAWLT EMARA, M.D.\*\* and AHMAD M. EL-SADAT, M.D.\*

*The Departments of Plastic & Reconstructive Surgery, Faculties of Medicine, Beni Suif\* and Cairo\*\* Universities*

### ABSTRACT

**Background:** The cleft lip nasal deformity presents a challenge to the pediatric plastic surgeon. The deformity is complex and involves all tissue layers. Controversy exists regarding the best time to perform the surgical correction of these deformities. There is a consensus that these nasal deformities are better to be dealt with along with repair of cleft lip. This is a study to evaluate the concept of repairing unilateral cleft lip simultaneously with the nasal soft tissue deformity and to evaluate the procedure regarding; cosmesis, symmetry, function and parents' satisfaction.

**Methods:** Twenty patients with unilateral cleft lip nasal deformity. Their ages range at the time of surgery was from (3) months to (12) years old of any sex, not operated upon before, non-syndromic with no comorbidity and no associated cleft palate. All procedures were done under general anesthesia with oral centrally located endotracheal intubation and I.V line. Lip repair was done using Millard rotation advancement repair as described by Mulliken and Martinez-Perez for all patients. This modification gave the chance to elongate the shortened columella. Primary nasal repair was done using McComb's technique, in which we freed the nasal skin from the nasal bone and cartilage through incision in the buccal sulcus. The scissors were also passed up through the columella to free the skin from the medial crus and dome of the alar cartilage. The extent of the nasal dissection was from the alar rim over the nasal tip and up to the nasion on the cleft-side hemi-nose.

**Conclusion:** The post-operative frontal and basal views showed that all cases in the study yielded excellent to fair results based on the symmetry of the nostrils. The overall parent's satisfaction was excellent.

Based on the finding of this study we recommend the use of primary repair of cleft lip nasal deformity in all cases with cleft lip-nose for its better aesthetic results and balanced nasal growth that it yields.

**Key Words:** Cleft lip nose – Primary cleft lip nasal deformity repair.

### INTRODUCTION

Cleft lip nasal deformity is a patho-physiological deformity of cleft lip that necessarily accom-

panies it. It is caused by displacement of alar cartilage and abnormal positioning of the columella, nasal septum, and lower skeleton of the nose. Among these, the abnormal position of alar cartilage is the most significant cause of nasal deformity [1].

The cleft lip nasal deformity presents a challenge to the pediatric plastic surgeon. The deformity is complex and involves all tissue layers, including skeletal platform, inner lining, osseocartilaginous structure and overlying skin. It is often the characteristic cleft nasal deformity that is noticeable to the observer after a well performed cleft lip repair.

Corrections of nasal deformities involve solving many complex problems including malposition of exterior nose, deformity of nasal tip, deviation of the ala on the cleft side and septal deformity. The stigma of the patient with cleft is sustained mainly by the asymmetry of the nasal, entrances, many operations some of which cause extensive additional scarring have been suggested for removing this typical feature in patients with cleft [2].

Controversy exists regarding the best time to perform the surgical correction of these deformities. When this is done sometime after cleft lip repair, open or external rhinoplasty is the best approach. It allows accurate repositioning and secure stabilization of key anatomical structures under direct vision [3].

The great multitude of rhinoplasty techniques developed since the 1920s serves as a prove of the difficult nature of the secondary cleft rhinoplasty. Among the controversies encountered in managing this problem is the timing of intervention for nasal

deformities correction. With improvement in cleft lip surgery, there was a growing interest for correction of the nose at the time of lip repair. These trials was hindered by the risk of growth interruption and the relapse of the deformity after primary repair [4].

Now, there is a consensus that these nasal deformities are better to be dealt with along with repair of cleft lip [5].

It was thought that primary correction of nasal deformity in cleft lip patients would cause developmental impairment of the nose. It is now widely accepted that simultaneous correction of the cleft lip nasal deformity has no adverse effect on nasal growth [6].

Moreover, in the last two decades, there has been a re-appraisal to the concept of primary rhinoplasty in unilateral cleft lip management due to its superior results in nasal symmetry. Senior cleft surgeons, as Millard, McComb and Salzer provided encouraging results after reviewing the long term results of primary repair. They proved that there was no interruption of growth by early surgery and reported stable results up to 18 years after surgery [7-9].

Primary correction of the nasal deformity at the same time of lip repair has gained popularity, aiming at early restoration of the symmetry by lifting the alar cartilage and lengthening the columella on the cleft side [10].

Primary cleft lip nasal surgery result in a more symmetrical nose and a better overall appearance early in life of a patient with cleft lip nasal deformity. Even when completion rhinoplasty is required after nasal growth is complete, the deformity at this time is less severe and more amenable to a better final result [11].

## MATERIAL AND METHODS

This study was conducted on twenty patients with unilateral cleft lip nasal deformity aged from (3) months to (12) years old of any sex, not operated upon before.

Twenty patients the youngest was three months and the eldest was one year, non syndromic with no comorbidity and no associated cleft palate.

They were 12 males (60%) and 8 females (40%). Parent consanguinity was present in 6 of

the 20 cases which means that about 30% of cleft cases in the study came from consanguineous marriage. Left-sided cleft cases were 13 patients (65%) while right-sided cleft cases were 7 patients (35%).

All procedures were done under general anesthesia with oral centrally located endotracheal intubation and I.V line.

Full history taking including prenatal history, full clinical examination excluding cardiac, respiratory, renal, hepatic problems and syndromes.

Local examination included type of cleft lip by using Millard's modification of Kernahan's and Elsayh's striped (Y) classification. State of alar cartilage (buckling or splaying). State of columella (shortened or deviated).

Preoperative investigations in form of complete blood picture, bleeding time, clotting time, liver function tests, kidney function tests and echocardiography to exclude cardiac anomalies were done.

All patients were photographed preoperatively from frontal and basal views.

### *Operative technique:*

All procedures were done under general anesthesia with oral centrally located endotracheal intubation and I.V line. Lip repair was done using Millard rotation advancement repair as described by Mulliken and Martinez-Perez (1999) for all patients. This modification gave the chance to elongate the shortened columella (Fig.1).

Primary nasal repair was done using McComb's technique, in which we freed the nasal skin from the nasal bone and cartilage through the incision in the upper buccal sulcus.

The scissors were also passed up through the columella to free the skin from the medial crus and dome of the alar cartilage. The extent of the nasal dissection was from the alar rim over the nasal tip and up to the nasion on the cleft-side hemi-nose (Fig. 2).

### *Assessment of result:*

*Intervals between visits were:* Weekly in the 1<sup>st</sup> month, 2 times monthly in the 2<sup>nd</sup> month then monthly in the following 4 months.

Photo documentation post-operatively was performed. Sets of photographs included front and basal "worm eye's" views.

The photo set that was used for measurement was the photo of the last follow-up. In that set, linear measurements were be served to assess the symmetry. Linear measurements included: The length of the hemi columella and the alar base placement. These measurements were obtained on a magnified scale, by projecting the basal view of the patient on a screen, copying the view on a white paper, fixing the points of interest, then obtaining the measurements. The unit was the "length in cm" (magnified view). There was no need to have a control for linear measurements, since the actual value was not our goal; the goal was to compare between the cleft and the normal sides. Symmetry of nostril was assessed by comparing the cleft side hemi-columellar and alar base lengths with normal side lengths, then calculating a symmetry percentage between both sides (Fig. 3).

Parent's satisfaction was assessed by parent questionnaire, if it is excellent fair or not satisfied.

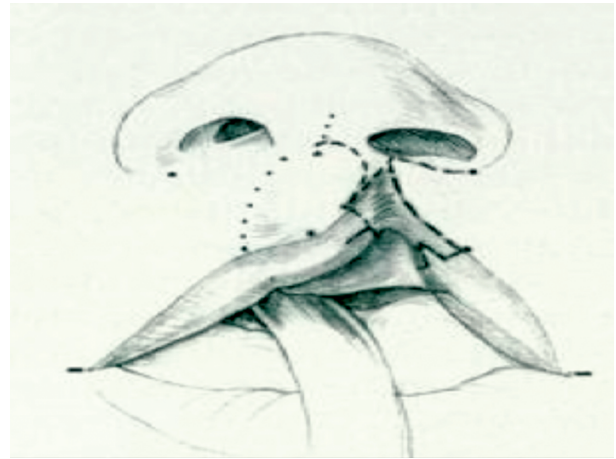

Fig. (1): Marking for lip repair.

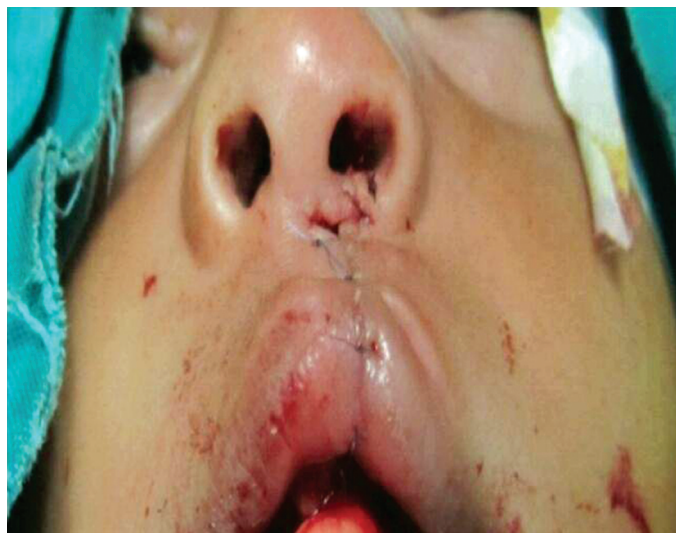
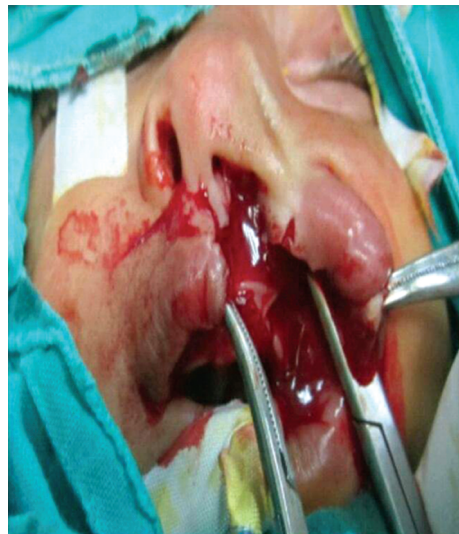
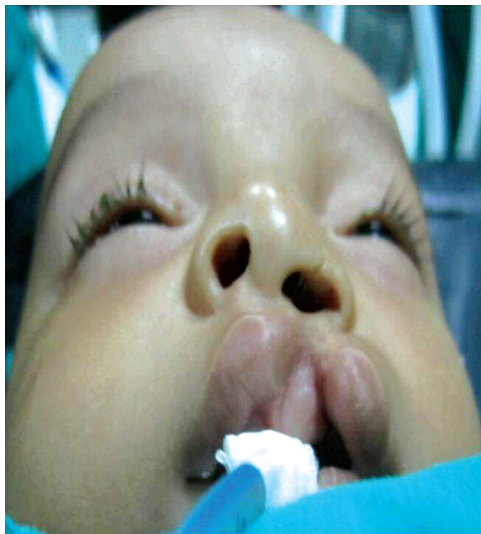Fig. (2): McComb's technique.



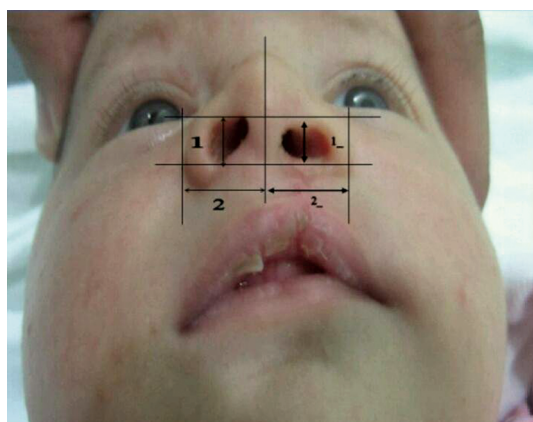


Fig. (3): Linear measures of assessment of symmetry.

## RESULTS

All cases in the study yielded excellent to fair results based on the symmetry of the nostrils. Symmetry percentage  $\geq 85\%$  is considered excellent & 75-84% good & 65-74% fair and  $\leq 64\%$  asymmetric.

Thirteen patients had an excellent correction of the width of the nostril on the affected side as compared to the normal side (65%). Four patients had a good correction of the nostril width on the cleft side (20%). Two patients had a fair correction of the nostril width (10%), while only one

patient had unsatisfactory correction (5%) (Table 1) (Fig. 4).

The overall parent's satisfaction was excellent in seventeen patients (85%), fair results in two patients (10%) and only one case (5%) they were not satisfied.

*The complications that were encountered in the postoperative period included:*

Early complication appeared immediately postoperative in form of nasal obstruction and discharge in two cases, that required treatment with nasal drops (Xylometazoline HCL 0.05%) for 3 days.

The day after surgery one case presented with edema and hematoma of dorsum of nose on cleft side that resolved after receiving antibiotic therapy (amoxicillin/clavulanate 50mg/kg) for one week and local application of (Recombinant Hirudin 280iu/100gm). The other seventeen cases didn't have any problem as regard the lip and nose.

Concerning lip scar, eighteen patients had excellent scars. While one case had fair lip scar and another case with unsatisfactory notched lip scar that needs notch repair.

None of the patients had wound dehiscence, hypertrophic scarring or keloid formation.

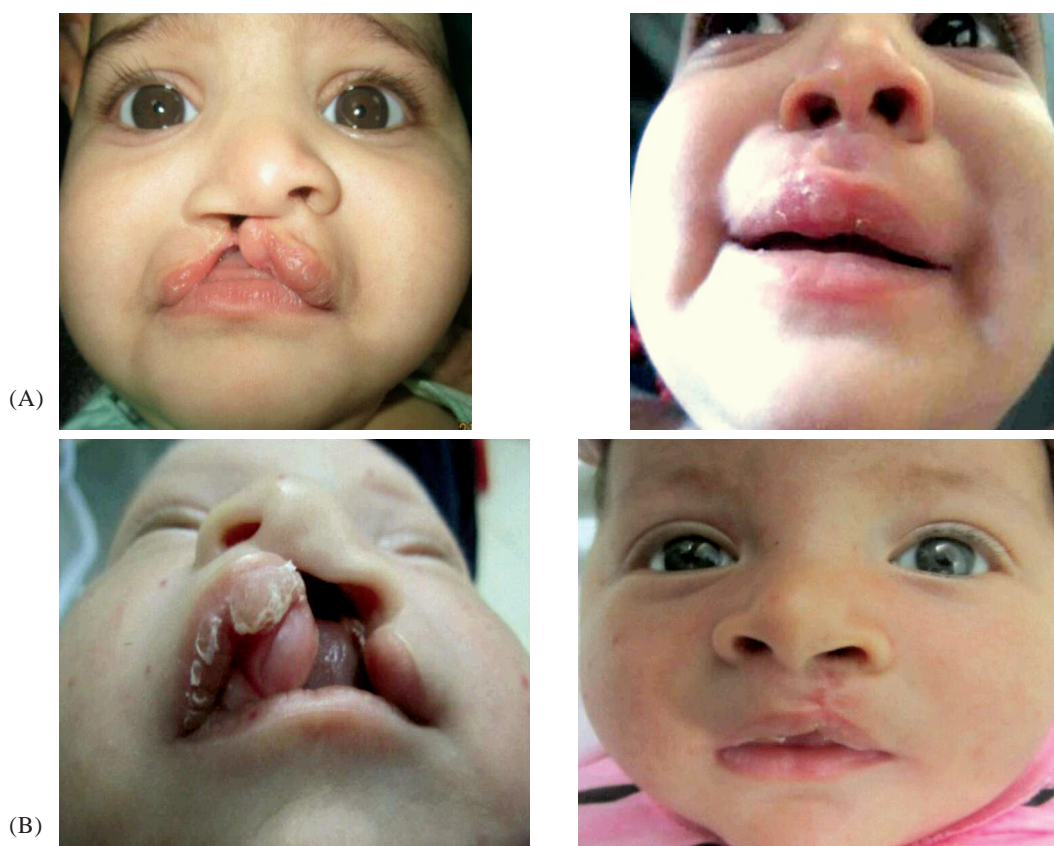

Fig. (4): Pre and (6) months postoperative view.



Table (1): Assessment of result and percentage of symmetry.

No.	Age	Last F/U	Normal HCL	Cleft. HCL	N. ABL	C. ABL	Sym. %
1	3m. old	6	1.5	1.3	3.5	3.3	81
2	2y. old	6	1	0.8	2	1.5	60
3	9m. old	8	1	0.8	2.5	2.2	70
4	3m. old	6	1.7	1.7	3.5	3.4	97
5	7m. old	6	1	0.8	1.5	1.5	80
6	18m. old	7	1	0.9	2.5	2.3	82
7	3m. old	6	2	1.8	3	2.8	84
8	9m. old	6	1.5	1.2	3.5	4	91
9	3m. old	6	1.5	1.3	3.5	3.9	96
10	9m. old	6	1.5	1	2.5	2.5	67
11	3m. old	6	1.5	1.2	3	3.2	85
12	12m. old	6	1	1	3.2	3	93
13	3m. old	6	1	0.9	2	2	90
14	4m. old	7	1	1	2.5	2.5	100
15	4m. old	6	1.6	1.4	2.5	2.5	87
16	9m. old	7	1.5	1.3	3	3.2	92
17	6m. old	6	1.7	1.5	2.7	3	98
18	7m. old	7	1.5	1.5	2	2	100
19	7m. old	7	1	0.8	3	3.2	85
20	6m. old	6	1	0.9	2.5	2.5	90

## DISCUSSION

Primary nasal repair in unilateral cleft lip has gone in the last seven decades through cycles of development and appraisal, criticism and discouragement then finally reappraisal.

Seventy years ago, the methods of cleft lip repair started to improve dramatically. While these methods continued to improve, attempts were also made to correct the associated nasal deformity. Different techniques were then described including skeletal repositioning with or without soft tissue reshaping [7].

Then came the time when criticism of the concept evolved, based on the results that obtained of some cases and showed recurrent cleft lip nasal deformity with additional scarring and stenosis that resulted from this type of early surgery [4].

These words by a famous cleft surgeon as McComb, represent the disappointing results obtained, suppressing the previous encouragement of the evolving concept.

In addition, the risk of growth impairment to the underlying delicate nasal cartilages remained in question and consequently applied constraints against primary correction. Accordingly, primary correction has been discouraged for these two reasons, relapse and growth impairment [12].

Relapse was almost a fact and growth impairment was a theoretical fear, that needed research to confirm. This experience with primary repair had led most surgeons to postpone the correction of the nasal deformity until nasal growth is complete.

The concept of primary repair of the nasal deformity was then reappraised after the long-term results were published. McComb and Salyer reported excellent results on reviewing their patients [8,9].

Byrd and Salomon's studies have disproved the claim that "Early nasal surgery affects growth". Primary nasal surgery results in a more symmetrical nose and a better overall appearance early in life. Also when a final rhinoplasty is required after nasal growth is complete, the deformity at that time is less severe and more amenable to a better final result [13].

Moreover in support of early cleft lip nose repair, McComb reviewed his first (10) consecutive cases after (18) years. His results supported the observation that nasal growth on the cleft side is not affected by the early primary nasal surgery [14].

The recent literature reports that nasal reconstruction at the time of primary lip repair improves the immediate appearance of the nose and has a positive effect on long-term growth, as the course of abnormal nasal growth is altered and a less severe curvature of the nose is observed in the adolescent years [15].

As regarding nostril stenosis, it happened to some degree at the level of the piriform aperture, but most of these cases are asymptomatic. Salyer rightfully underscored the risk of nostril stenosis and he recommended leaving the nostril slightly larger because tightening a laterally displaced alar base is easier than secondary correction of a tight external naris [16].

With these results in hand, with the embarrassment of the children with un-repaired cleft nasal deformity and with the increasing resistance of adult cartilages for reshaping, the concept of primary rhinoplasty was reestablished [17].

The aim of this study is to assess the results of repairing unilateral cleft lip nasal deformity simultaneously with lip repair according symmetry, function and parent's satisfaction. This prospective study was conducted on 20 patients.

The demographic characteristics of our 20 patients showed male to female ratio of 1.5: 1, left side to right side ratio of 1.8: 1, and isolated cleft lip to cleft lip and palate of 1: 1.2. The side and gender incidences are similar to the figures of the general population reported by Marazita and Moon-ey [18].

Cases distribution through parent consanguinity showed that, 30% of this study cases came from consanguineous marriage.

Jaber et al., found that 34% of their cases came from consanguineous marriage and they reported that although the incidence of cleft lip and palate in the general population is 1/1000, the incidence among children of consanguineous parents is 10/1000 [19].

Still, controversy remains as to the optimum corrective approach, the best techniques for exposure and repair, and, most significantly, the timing of the correction [20].

The choice of technique is a controversial issue and a substance of debate. The predilection of a surgeon to a technique is tailored to his learning curve and experience.

Millard in 1955, popularized rotation advancement concept that preserved the Cupid's bow and philtral dimple and reduced tension on the lip, thereby producing a more consistent cosmetic result [21].

Here, lip repair was done using Millard rotation advancement repair as described by Mulliken and Martinez-Perez for all patients.

This technique provided minimal or no discarded tissue; the technique is flexible and adaptable; it allows creation of a normal-looking Cupid's bow [22].

Many cleft surgeons presented new techniques for correction of the nasal deformity and mentioned that they achieved good results, however; McComb utilized the same incisions used for lip repair his primary rhinoplasties. This evidently is least invasive and minimizes scarring and fibrosis, especially that which can occur in the nasal vestibule with subsequent narrowing of the nostril [9].

It may be easy for world renowned surgeon as McComb with his respectable abilities and experience to use lip incisions, however, for teaching curves, exposure is quite limited unless additional incisions are made so that there was an increasing tendency among cleft surgeons to modify the classic

Millard technique of lip repair to suit their approaches to the nasal deformity [23,24].

Nasal deformity was repaired using McComb's technique in which, nasal skin was freed from the nasal bone and cartilage through the incision in the upper buccal sulcus. The scissors were also passed up through the columella to free the skin from the medial crus and dome of the alar cartilage. The extent of the nasal dissection was from the alar rim over the nasal tip and up to the nasion on the cleft-side hemi-nose.

Concerning this study, the valuable advantage of using McComb's technique in nasal repair is that it is a simple technique appropriate for our restricted resources and limited experiences.

Moreover this procedure was suitable in dealing with the delicate alar cartilage especially in young age.

The method used in this study consisted of simple linear measurements obtained by projecting the photograph of the basal view. Linear measurements included the hemi-columellar length and the location of the alar base.

Comparing the values in the repaired side to the normal side can give an indication of the symmetry obtained.

We used "Real Size Digital Photographs" in this study rather than direct measurement as the method of data acquisition due to several reasons.

*First*, the recorded data can be kept as a computer file which can be retrieved for later referral or recheck; one cannot refer back to take nasal measurements from a child whose dimensions are continuously changing.

*Second*, the age group of children in this study (3 months to 2 years) is very difficult to control for more than a few seconds; this would allow for taking a shot but not enough to obtain direct nasal measurements or do an aesthetic evaluation.

*Third*, assessment from digital photograph makes it possible to crop the photo, using ordinary computer programs, limiting the assessment to the nasolabial area. This eliminates the effect of other facial features from influencing the score that the rater records to the examined feature.

*Fourth*, assessment from photographs makes it possible for the examiner to be shown the full series of patients before starting assessment. This makes him familiar with the full range of the deformity before starting assessment.

Postoperative results appeared encouraging in most series. Satisfactory symmetry of the nose can be obtained with high rate of success after primary repair [17].

Results obtained in this study showed reasonable results through a median follow-up period of (7) months.

Total measurements that obtained showed excellent symmetry among 13 cases (65%) and 6 cases (30%) showed good to fair symmetry. Only one case that need secondary surgery at adolescence.

Armstrong and Clark, reported the need for secondary surgery at adolescence.

But in patients who underwent primary nasal correction with lip closure, the extent of further correction is limited to touch-ups and fine-tuning with excellent results.

Otherwise, leaving the nose untouched can lead to a long standing complex nasal deformity, with mature cartilage, resistant to molding and reshaping.

The only deformity that is left for adult life is the nasal septal deviation. Definitive open septorhinoplasty should be delayed until the teenage years and after maxillary advancement, should it be necessary [14].

Another factor that encourages early intervention is the absence of complications, such as skin necrosis, wound infection or breakdown and vestibular stenosis. In this study, no wound infection, break down or skin loss was encountered.

However, in two patients, nasal obstruction and discharge was observed immediately postoperative, that required treatment with nasal drops (Xylometazoline HCL 0.05%) for 3 days. The day after surgery one case presented with edema and hematoma of dorsum of nose on cleft side that resolved after receiving antibiotic therapy (amoxicillin/clavulanate 50mg/kg) for one week and local application of (Recombinant Hirudin 280iu/100gm).

Finally, the concept of primary correction of the nasal deformity at the time of lip repair is attractive. It provides an opportunity to obtain symmetry, with pliable cartilage that can be shaped without difficulty. Perfect alar lift remains to be the cornerstone in such surgery, to be followed by closure of the nasal floor. The classic Millard advancement rotation technique for repair of uni-

lateral cleft lip can either be utilized to approach the nose, or modified by adding minimal incisions for wider exposure.

#### Conclusion:

Management of the cleft lip nasal deformity is a challenging part in cleft lip and palate care. Fortunately many techniques are currently available for the treatment of the nasal deformity. Also there are many methods for postoperative evaluation of results, but there is no consensus on a comprehensive method for assessment of results and comparison between techniques. The choice between techniques is difficult and mainly based on surgeon's training and preference rather than on evidence-based data to support and recommend one technique or the other.

Based on the finding of this study we recommend the use of primary nasal repair in all cases of cleft lip-nose for the better aesthetic results and balanced nasal growth that it yields. However because of the limited number of patients and short period of follow-up our results should be taken cautiously. Further studies of the same design but with larger number of patients and longer period of follow-up are also recommended.

#### REFERENCES

- 1- Kim S.K: "Primary correction of unilateral cleft lip nasal deformity in Asian patients". *Anthropometric evaluation. Plast. Reconstr. Surg.*, 6: 114. 2004.
- 2- Gubisch W: "The triple swing flap technique to correct the asymmetry of unilateral cleft lip nose deformities". *Scand J. Plast. Reconstr. Hand Surg.*, 32: 287-294, 1998.
- 3- Thomas C. and Mishra P.: "Open tip rhinoplasty along with the repair of cleft lip in cleft lip and palate cases". *Br. J. Plast. Surg.*, 53: 1-6. 2000.
- 4- McComb H.: "Primary repair of cleft lip nasal deformity". In Kernahan D.A. and Rosenstein S.W. (Eds.). *Cleft lip and palate. Williams & Wilkins Chapter, 22: pp. 167-180. 1990.*
- 5- Thomas C.: "Primary rhinoplasty by open approach with repair of bilateral complete cleft lip". *J. of Craniofac. Surg., Suppl 2:1715-8, Sept 2009.*
- 6- Kim S.K.: "Primary correction of unilateral cleft lip nasal deformity in Asian patients". *Anthropometric evaluation. Plast. Reconstr. Surg.*, 6:114, 2004.
- 7- Millard R.: "Unilateral cleft lip deformity". McCarthy, *Plastic Surgery, Volume 4, WB Saunders, Philadelphia, PA, 53/2708-14, 1990.*
- 8- Salyer K.E.: "Early and Late Treatment of unilateral cleft nasal deformity". *Cleft Palate Craniofac. J.*, 29: 556, 1992.
- 9- McComb H.: "Primary repair of the unilateral cleft lip nose: Completion of a longitudinal study". *Cleft Lip Craniofac. J.*, 33: 23-30, 1996.



- 10- Lun-Jou Lo: "Primary correction of the unilateral cleft lip nasal deformity: Achieving the excellence". *Chang Gung Med J.*, Vol. 29 No. 3 May 2006.
- 11- LaRossa D. and Donath G.: "Primary nasoplasty in unilateral and bilateral cleft nasal deformity". *Clin. Plast. Surg.*, 20 (4): 781-791, 1993.
- 12- Brusse C.A., Vander Werff J.F.A., Stevens H.P.J., et al.: "Symmetry and morbidity assessment of unilateral complete cleft lip nose corrected with or without primary nasal correction". *Cleft Palate-Craniofac J.*, 36 (4): 361-366, 1999.
- 13- Byrd H.S. and Salomon J.: "Primary correction of the unilateral cleft nasal deformity". *Plast. Reconstr. Surg. J.*, 16: 1276-1286. 2000.
- 14- Patil P.G., Patil S.P. and Sarin S.: "Naso-alveolar molding and long-term post-surgical esthetics for unilateral cleft lip/palate: 5-year follow-up". *J. Prosthodont.*, 20 (7): 577-82. Oct 2011.
- 15- Haddock N.T., McRae M.H. and Cutting C.B.: "Long-term effect of primary cleft rhinoplasty on secondary cleft rhinoplasty in patients with unilateral cleft lip-cleft palate". *Plast. Reconstr. Surg.* Mar., 129 (3): 740-8, 2012.
- 16- Salyer K.E.: "Unilateral cleft lip-nose repair long term outcome". *Clin. Plast. Surg.*, 31: 191-208, 2004.
- 17- El-Bestar M. and Mansour O.: "cleft lip nasal deformity: primary repair". *Egypt, J. Plast. Reconstr. Surg.*, Vol. 28, No. 1 January 15-21, 2004.
- 18- Marazita M.L. and Mooney M.P.: "Current concepts in the embryology and genetics of cleft lip and palate". *Clin. Plast. Surg.*, 31: 125-140, 2004.
- 19- Jaber L., Nahmani A., Halpern G., et al.: "Facial clefting in an Arab town in Israel". *Clin. Genet.*, 61: 448-453, 2002
- 20- Chowchuen B., Keinprasit C. and Pradubwong S.: "Primary unilateral cleft lip-nose repair": The Tawanchai cleft center's integrated and functional reconstruction. *J. Med. Assoc. Thai.*, 93 (Suppl 4): S34-45, Oct 2010.
- 21- Byrd H.S.: "Cleft Lips: Primary deformities (overview)". *Selected Readings in Plastic Surgery*, 8 (21): 1-37, 1997.
- 22- Mulliken J.B. and Martinez-Perez D.: "The principle of rotation advancement for repair of unilateral complete cleft lip and nasal deformity: Technical variations and analysis of results". *Plast. Reconstr. Surg. J.*, 104: 1247, 1999.
- 23- Shih C.W. and Sykes J.M.: "Correction of the cleft lip nasal deformity". *Facial Plast. Surg. J.*, 18 (4): 253-262, 2002.
- 24- Wong F.K. and Hagg U.: "An update on the etiology of oro-facial clefts". *Hong Kong Medical Journal Hong Kong Academy of Medicine*, 10: 331-336, 2004.